

## AN OBSERVATIONAL PROSPECTIVE STUDY ON SPLIT THICKNESS SKIN GRAFT AFTER EXCISION OF REMOVAL OF NAIL PLATES IN CHRONIC PARONYCHIA OF GREAT TOE IN WESTERN ODISHA

Meher Bhanjan Kumar<sup>1</sup>, Meher Sasmita<sup>2</sup>, Mohanty Saroj Ranjan<sup>3</sup>, Swain Rakesh Ranjan<sup>4</sup>

Received : 30/04/2023  
Received in revised form : 02/06/2023  
Accepted : 14/06/2023

**Keywords:**  
Clinical, Ultrasound Methods, estimation of Fetal Weight, term Pregnancy.

Corresponding Author:  
**Dr. Rakesh Ranjan Swain,**  
Email: rrakesh.swain19@gmail.com

DOI: 10.47009/jamp.2023.5.3.466

Source of Support: Nil,  
Conflict of Interest: None declared

*Int J Acad Med Pharm*  
2023; 5 (3); 2376-2380



<sup>1</sup>Assistant Professor, Department of General Surgery, BBMCH, Bolangir, Odisha, India.

<sup>2</sup>Assistant Professor, Department of Pulmonary Medicine, BBMCH, Bolangir, Odisha, India.

<sup>3</sup>Assistant Professor, Department of General Medicine, BBMCH, Bolangir, Odisha, India.

<sup>4</sup>Assistant Professor, Department of General Surgery, BBMCH, Bolangir, Odisha, India.

### Abstract

**Background:** Paronychia is an acute inflammatory condition of nail of toe or fingers. most commonly it is developed in person having ingrowing toe nail , labourer working in mud, farmers and house wife with chronic water and dust contamination. There are lot of traetment procedure available and also majority of them cure by medication and sometime needs incision and drainage but some chronic paronychia of great toe does not heal and cronic recurrence of disease happens.so they need operative procedure for cure of the disease. Patients suffer from chronic severe pain in fingers and toes. We conducted a modified surgical technique for patient having chronic paronychia of great toe. **Materials and Methods:** This study was conducted among 60 patients of chronic paronychia aged between 15 to 60 years of age, from January 2018 to January 2021. These patients were operated and followed for about 2 year and observed for wound healing ,skin grafting wound healing results, relief from pain and discharge, cosmetic acceptance and recurrence of disease. Clinical data was recorded in case record by conducting descriptive analysis by asking questions to the patients. Results were analysed in terms of wound healing ,skin grafting results, relief from pain and discharge, cosmetic acceptance and recurrence of disease if any. **Results:** Postoperative result showed that 96% of patients had wound healing and skin grafting successand take off, 98% relief of pain ,2% graft failure due to infection,96% cosmetic acceptance and only 2% recurrence in patient having skin grafting failure due to infection. **Conclusion:** In our study, treatment of chronic paronychia of great toe was well-accepted by all patients due to absence of any defect and deformity of operated area with early healing, comfort to operated area and permanent relief from chronic pain. Cosmetic appearance of operated area was well-accepted by all patients, and recurrence was very less. This surgical technique provide suitable treatment for recurrent chronic paronychia of great toe. So, this method of treatment is better to perform for cure of chronic paronychia of great toe.

## INTRODUCTION

Paronychia is an acute inflammatory condition of nail of toe or fingers.<sup>[1]</sup> Most commonly it is developed in person having ingrowing toe nail , labourer working in mud, farmers and house wife with chronic water and dust contamination. There are various factors responsible for chronic paronychia like chronic trauma, ingrowing toe nail, multiple times exposure to mud , water or any chemical.<sup>[2]</sup>

Chronic paronychia is considered in which patients suffers from repeated attack of inflammation of toes or fingers,most commonly in great toes, for a period more than 6weeks.

Patients are usually negligence to take care of their toes and fingers are suffer from chronic paronychia. Chronic paronychia is also found in hair dressers.<sup>[3]</sup> and food handlers.<sup>[4]</sup> Patients usually comes to the hospital with chronic swelling, pain and deformity of tissue in lateral or medial side of the nail. They all have a long history of application of steroid,

antibacterial and few having antifungal ointment application. Few of them were history of incision and drainage. Some were taking antibiotic and antifungal orally for a prolong period.

Paronychia presented with abscess usually responds well to incision and drainage. Paronychia develops repeatedly due to ingrowing toe nail are usually not respondent to oral medication or any surgical procedure and develops chronic paronychia. Chronic paronychia never responds to medical treatment and it mostly requires surgical treatment.

Complete cure of chronic paronychia is challenging to the surgeons always and chances of decrease its surgical reputations. In our surgical OPD we get patients with recurrence of chronic paronychia having previously multiple surgery like excision of nail fold, incision and drainage and presented with pain, discomfort, and morbidity, which hinders the normal work and activities.

There are various treatment methods are available in market for treatment of chronic paronychia having different outcomes and merits such as en bloc excision of nailfold.<sup>[5]</sup> square flap technique.<sup>[6]</sup> eponychial marsupialization.<sup>[7]</sup> Swiss roll technique<sup>8</sup> laser treatment.<sup>[9]</sup> and silver nitrate chemical cauterization.<sup>[10]</sup> This study was conducted in our surgery department of BHIMA BHOI MEDICAL COLLEGE, Balangir to find out the outcome of a modified surgical technique in chronic paronychia of great toe. our procedure involves excision of diseased surrounding tissue with partial removal of nail bed and split-thickness skin graft (STSG) was carried out.

#### **Aim of the Study**

To study the for wound healing, skin grafting wound healing results, relief from pain and discharge, cosmetic acceptance and recurrence of disease.

## **MATERIALS AND METHODS**

This is an observational prospective study. In our study we included 60 cases of Chronic paronychia of great toe of those between 15 to 65 years of age and sexes were included consecutively between January 2019 to January 2021 who were attended the outdoor department of general Surgery. All cases of chronic paronychia of great toe of foot were enrolled during the study period. These patients presented with pain, swelling, discomfort, deformity of nail and nail fold, and chronic discharge from nail fold. Each patient's history was taken, examined properly, and evaluated. Diseases like diabetes mellitus, hypertension, tuberculosis, chronic obstructive pulmonary diseases (COPD), any auto-immune disease, vascular diseases, central nervous system (CNS) diseases, serious myocardial problem, and chronic osteomyelitis of great toe phalanx bone were excluded. All

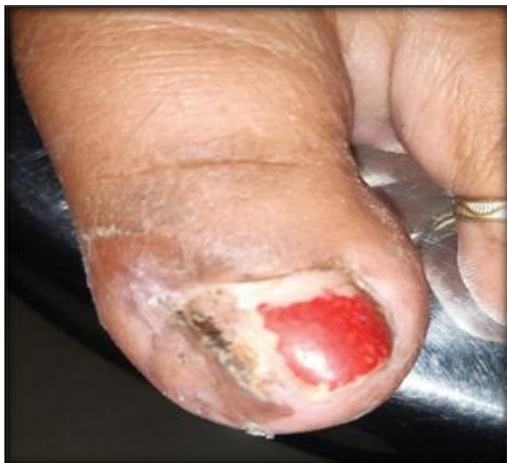50 patients were free of the abovementioned diseases. Patients were categorized as per age, sex,

and different sites of occurrence. X-ray of operated foot was done in all patients. Patients with osteomyelitis in phalanx bone of great toe were excluded from study. All patients preoperatively had normal hemogram, liver function test, renal function tests, normal chest X-ray, normal X-ray foot, and normal electrocardiogram. Counselling of all 50 patients were done about the risks and complications of surgery (peroperative and postoperative) like severe bleeding, loss of skin graft, permanent cosmetic deformity, keloid formation and severe infection of operated area, chronic pain of operated area, and complication of anesthesia. All patients agreed for surgery under local or spinal anesthesia. Written consent was taken from patient for excision of nail plate along with surrounding tissue of diseased great toe and STSG under local (great toe digital block) or spinal anesthesia. Part was prepared by hair shaving from knee to ankle joint. Part was cleaned with soap and water before 2 hours of surgery. Before procedure of surgery, sensitivity test of lidocaine hydrochloride was performed. Surgical procedure (excision of nail plate along with surrounding tissue of diseased great toe and STSG) was performed, patient was discharged from hospital after treatment, and follow-up done. During follow-up period, each patient was examined and asked questions, and clinical data was collected and recorded in a predesigned case record form. The data was entered in a Excel sheet, and descriptive analysis was done by using a statistical software in a personal computer.

#### **Surgical Procedure**

Surgery was performed under local anesthesia (5 mL of 2% lidocaine hydrochloride subcutaneous infiltration circumferentially at base of disease great toe or spinal anesthesia. Intravenous set of plastic tube was used as tourniquet, which was applied at base of great toe. Incision was given on distal phalanx of great toe, covering the lateral part of nail plate, diseased nail fold and anterior part of lateral nail fold, including approximately 1 mm of healthy margin. Incision was deepened till healthy soft tissue. Nail plate along with surrounding nail fold tissue was excised. After excision, on touching the depth of raw area, it was soft as compared with excised disease tissue. Raw area was irrigated with normal saline. About 2 mL of lidocaine was injected subcutaneously at donor area of leg or thigh required amount of STSG was measured same as raw area of great toe. Skin graft was taken from leg of same side. Donor area was covered with sterile dressing and bandage. STSG was washed with normal saline. Skin graft was applied on raw area of great toe and fixed with 3-0 curve cutting silk suture on margin of raw area. On the graft, paraffin tulle was applied, sterile cotton soaked with 5% povidone iodine solution applied over the tulle area, and tie over bolus dressing done. Tourniquet was removed. Again, bulky dressing was done, great toe was immobilized with plaster of Paris posterior slab below knee, and pressure bandage was applied on

great toe and foot . Post- operatively, patient was kept for 2 hours in indoor and after that point was discharged, and advised to take oral anti-biotics for 7 days, no walking on operated foot for 7 days elevation of operated foot during sleep for 7 days. Patient was called for stitches removal on 10th postoperative day. Stiches was removed on 10th postoperative day and assessed for whether skin graft was taken completely or partially after that area was dressed. Bandage of donor area was removed and assessed after that patient was advised for application of paraffin on donor area and operated great toe for 2 to 3 months. On 2nd week of follow-up, complete healing of operated area was found. Patient was called for follow-up every 2 weeks for 2 months, then monthly for 2 months, and finally every 4th month. During postoperative follow-up period, we assessed for skin graft take up, duration of wound healing, pain relief, cosmetic acceptance of operated toe, and recurrence of disease. On 10th postoperative skin graft was taken completely.



**Figure 1:** On 2nd week of follow-up complete healing of operated area data was collected and recorded during postoperative follow-up period

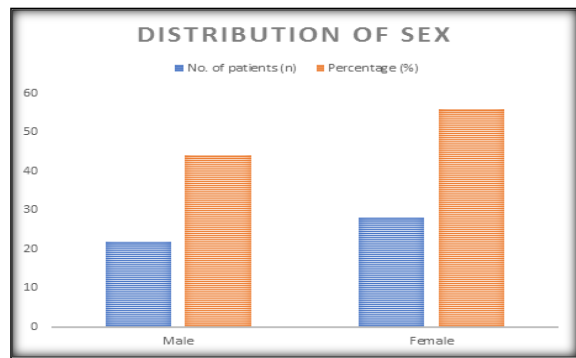
## RESULTS

### Gender Distribution

In our study, it was found that out of 50 patients suffering from chronic paronychia of great toe, gender distribution was 56% (n ¼ 28) are women and 44% n ¼ 22) are men (► Table 1).

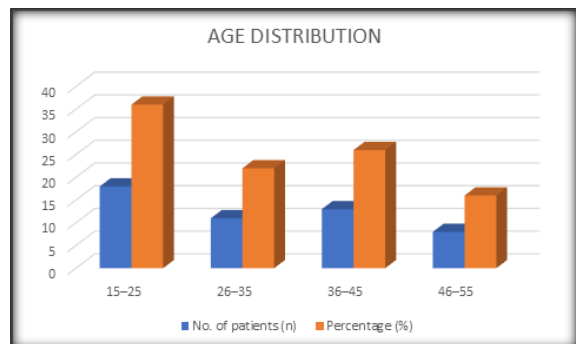
**Table 1:** Distribution of gender of chronic paronychia of great toe patients

Gender	No. of patients (n)	Percentage (%)
Male	22	44
Female	28	56



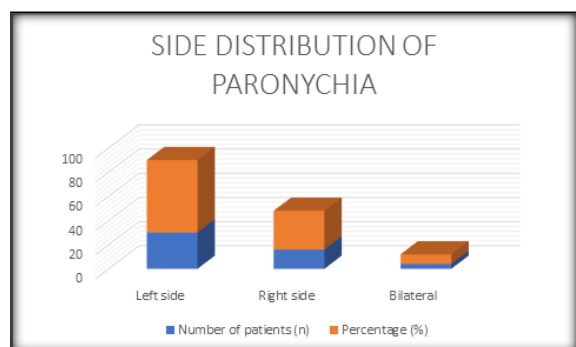
**Table 2:** Distribution of age group of patients with chronic paronychia of great toe

Age group in years	No. of patients (n)	Percentage (%)
15–25	18	36
26–35	11	22
36–45	13	26
46–55	8	16



**Table 3:** Side distribution of chronic paronychia of great toe patients

Side	Number of patients (n)	Percentage (%)
Left side	30	60
Right side	16	32
Bilateral	4	8



### Age Group Distribution

In this study, out of 50 patients who were suffering from chronic paronychia, age group distribution was 36% (n ¼ 18) in age between 15 to 25 years, 22% (n ¼ 11) in age between 26 to 35 years, 26% (n ¼ 13) in age between 36 to 45 years, and 16% (n ¼ 08) between age 46 to 55 years (► Table 2).

### Side Distribution

Out of the total patients (n = 50), side distribution of chronic paronychia of great toe was 60% (n = 30) on left side, 32% (n = 16) on right side, and 8% (n = 4) on bilateral involvement (► Table 3).

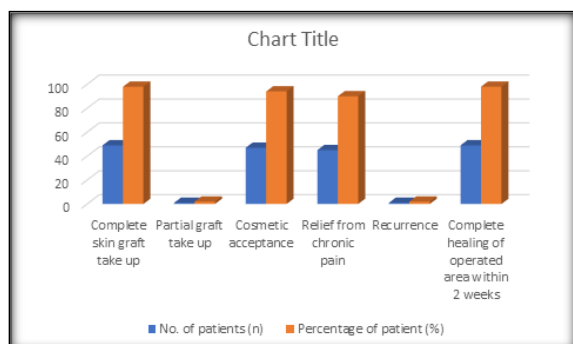
### Outcomes

In follow-up period, patients had different outcomes in terms of complete skin graft take up on 10th postoperative day (98%; n = 49), partial skin graft take up (2%; n = 2), and approximately 94% (n = 47) accepted the operated area. Relief from chronic pain of disease great toe (90%; n = 45) and complete healing of operated area of great toe and donor area within 2 weeks (98%; n = 49) (► Table 4).

## DISCUSSION

The nail plate is embedded by the proximal and lateral folds.<sup>16</sup> The lateral and proximal nail folds form a distally open frame for the growing nail.<sup>17</sup> Proximal nail fold is a wedge-shaped fold of skin lying on the dorsum of finger and toes, which covers approximately one-fourth of the total nail length. The skin on either side of the nail is an extension of the proximal nail fold and is known as the lateral nail fold. The stratum corneum of eponychium forms a thick rim of keratinous material, known as cuticle, around the margins of the proximal nail fold which along with the proximal and lateral folds provide protection against penetration of water Table 4 Different outcomes of patients of chronic paronychia of great toe treated with excision of nail plate along with surrounding tissue and STSG.

Different outcomes	No. of patients (n)	Percentage of patient (%)
Complete skin graft take up	49	98
Partial graft take up	1	2
Cosmetic acceptance	47	94
Relief from chronic pain	45	90
Recurrence	1	2
Complete healing of operated area within 2 weeks	49	98



Abbreviation: STSG, split thickness skin graft. and toxic chemicals.<sup>[11]</sup> Chronic inflammation of nail fold of great toe results from the disruption of the protective barrier between the nail and the nail fold.

Chronic paronychia is a multifactorial inflammatory condition primarily caused by exposure to environmental allergens or irritants.<sup>[12]</sup> Repeated several episodes of acute paronychia of great toe leads to chronicity. Chronic paronychia patients attended to our institute with duration of disease within 6 months to 3 years. On observation, it was found that longer the duration, more severe was the disease with more pain, multiple patchy scarring, multiple nodules, red tender nail fold, surrounding nail plate, swollen thick irregular nodular firm consistency with deformity. Some patients had previous history of nail fold surgery (excision of lateral nail fold) and after that suffered from recurrent paronychia. It was found that maximum number of patients (36%) were in age group between 15 to 25 years and more females had chronic paronychia as compared with male patients. In this study, we observed that out of 50 patients, left side of great toe is 60% (n = 30), right side 32% (n = 16), and 8% (n = 4) were bilateral great toe chronic paronychia. On follow-up of patients, it was observed and found that complete STSG taken up was 98% (n = 49), partial skin graft take up 2% (n = 2), complete healing of wound was 98% (n = 49), relief from chronic pain (as patient experienced before treatment) disease toe was 90% (n = 45), cosmetic acceptance of patients was 94% (n = 47), and recurrence of diseases was 2% (n = 2). About 2% (n = 2) had partial skin graft take off. These patients had delayed healing, which was managed by dressing by paraffin tulle. These delayed healing patients suffered from recurrence of disease after 6 months of follow-up.

At present, throughout the world, the most common surgical treatment for chronic paronychia is en bloc excision of nail and disease nail fold or only excision of diseased nail fold. In this method of surgery, raw area was created, and healing occurring was secondary which caused scarring surrounding the toenail. Scar tissue surrounding the toenail was less vascular, with very thin epithelium. As the scar tissue is usually dry, it is labile to injury and so the chances of recurrence of chronic paronychia. In our study, we performed partial excision of nail plate along with surrounding diseases nail fold followed by STSG of the raw area. In our surgical method of treatment, little modification as STSG was applied on secondary defect (raw area after excision). In our method, healing of wound was accelerated primarily by STSG, and patients did not require postoperative multiple close dressing of operated area. Some patients who had poor graft take up needed postoperative close dressing. Patients were comfortable postoperatively. Wound healing was excellent, and patients accepted postoperative cosmetic appearance of operated toe. All patients' donor areas healed without any donor area defect and deformity. Maximum patients got permanent relief from chronic pain of diseased toe, so their work efficacy improved. Recurrence of disease was very minimal.

## CONCLUSION

In our study, treatment of chronic paronychia of great toe was well-accepted by all patients due to absence of any defect and deformity of operated area with early healing, comfort to operated area and permanent relief from chronic pain. Cosmetic appearance of operated area was well-accepted by all patients, and recurrence was very less. This surgical technique provide suitable treatment for recurrent chronic paronychia of great toe. So, this method of treatment is better to perform for cure of chronic paronychia of great toe.

Conflict of Interest. None

## REFERENCES

1. É [Paronychia]. *Presse Med* 2014;43(11):1216–1222
2. Black JR. Paronychia. *Clin Podiatr Med Surg* 1995;12(02):183–187
3. Daniel CR III. Paronychia. *Dermatol Clin* 1985;3(03):461–464
4. Ferreira Vieira d’Almeida L, Papaiordanou F, Araújo Machado E, Loda G, Baran R, Nakamura R. Chronic paronychia treatment: square flap technique. *J Am Acad Dermatol* 2016;75(02):398–403
5. Keyser JJ, Eaton RG. Surgical cure of chronic paronychia by eponychial marsupialization. *Plast Reconstr Surg* 1976;58(01): 66–70
6. Pabari A, Duhard Iyer S, Khoo CT. Swiss roll technique for treatment of paronychia. *Tech Hand Up Extrem Surg* 2011;15(02):75–77
7. El-Komy MH, Samir N. 1064 Nd:YAG laser for the treatment of chronic paronychia: a pilot study. *Lasers Med Sci* 2015;30(05): 1623–1626
8. Sato N, Yuda J, Yamauchi N, et al. [Successful treatment with silver nitrate chemical cauterization for paronychia and granulation in a patient with chronic lymphocytic leukemia undergoing ibrutinib therapy]. *Rinsho Ketsueki* 2021;62(01):35–41
9. de Berker D. Nail anatomy. *Clin Dermatol* 2013;31(05):509–515
10. Haneke E. Anatomy of the nail unit and the nail biopsy. *Semin Cutan Med Surg* 2015;34(02):95–100
11. Baswan S, Kasting GB, Li SK, et al. Understanding the formidable nail barrier: A review of the nail microstructure, composition and diseases. *Mycoses* 2017;60(05):284–295
12. Macneal P, Milroy C. *Paronychia Drainage*. Treasure Island (FL): StatPearls Publishing; 2020.